

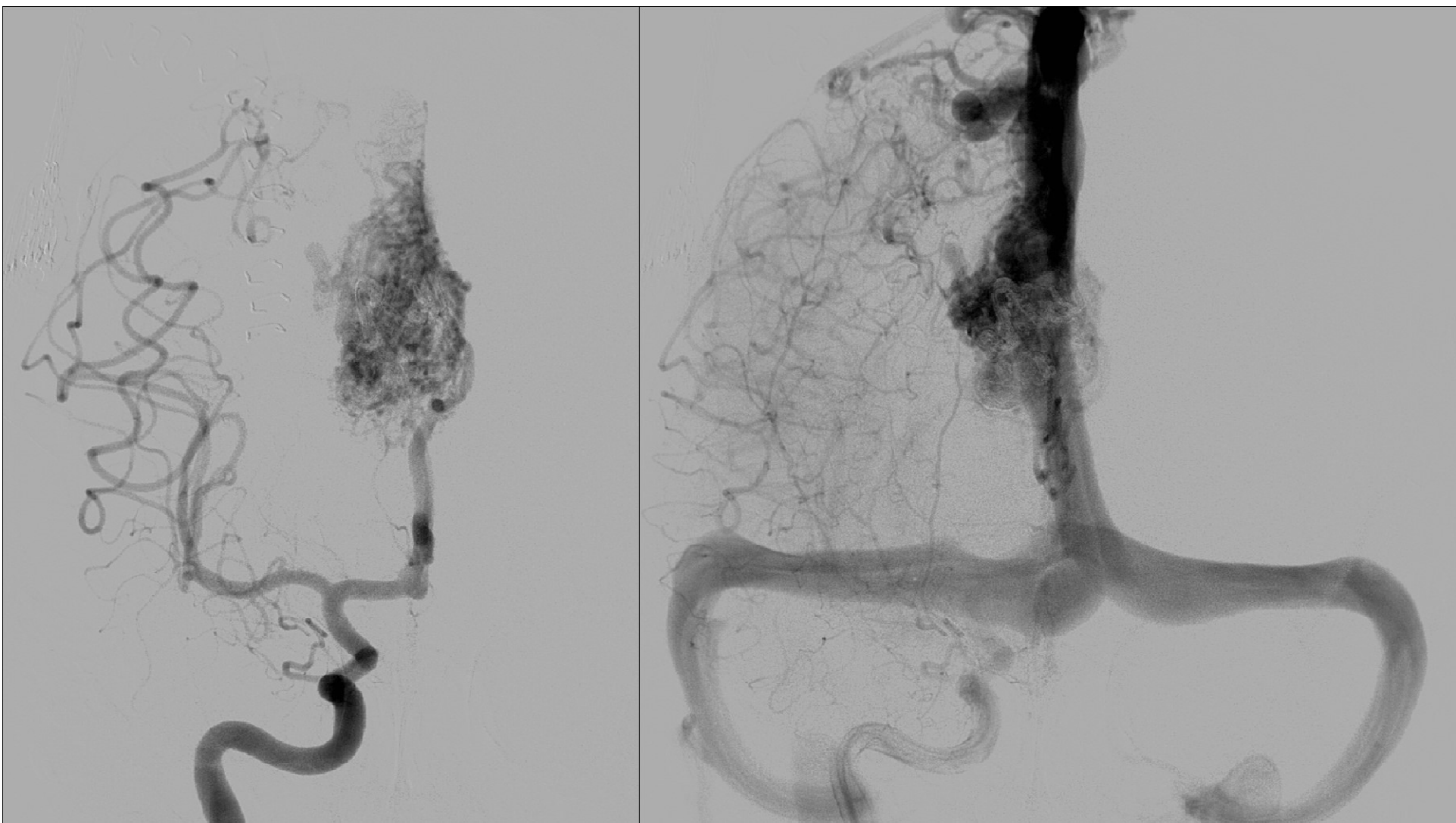
19 YO WITH PARENCHYMAL HEMATOMA

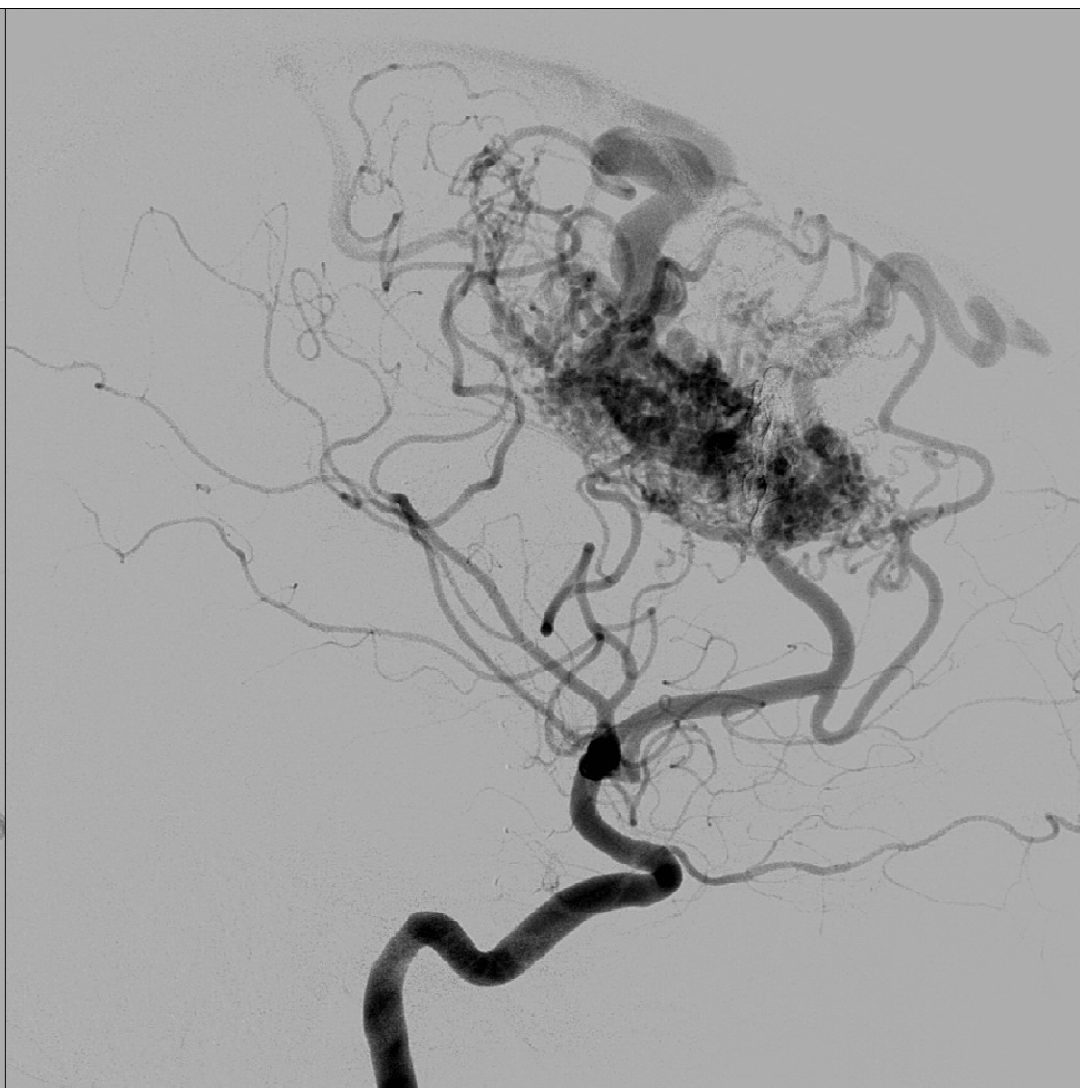
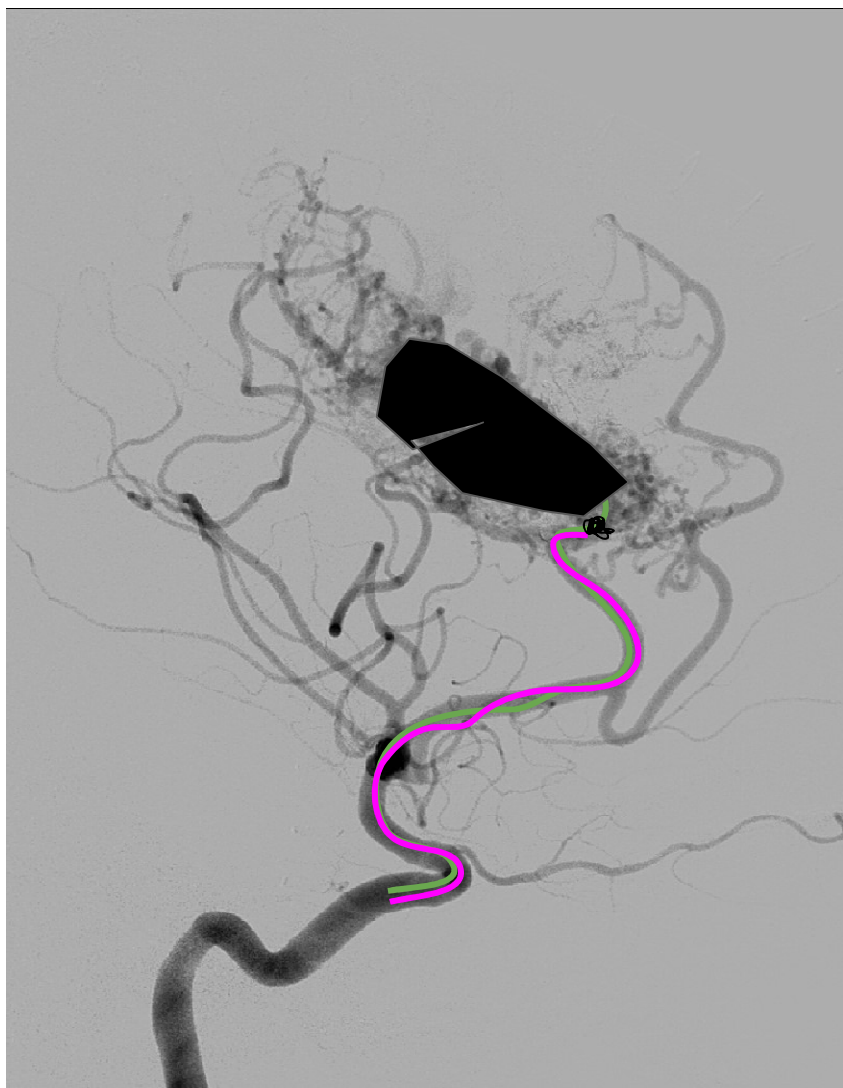
M. Moreu

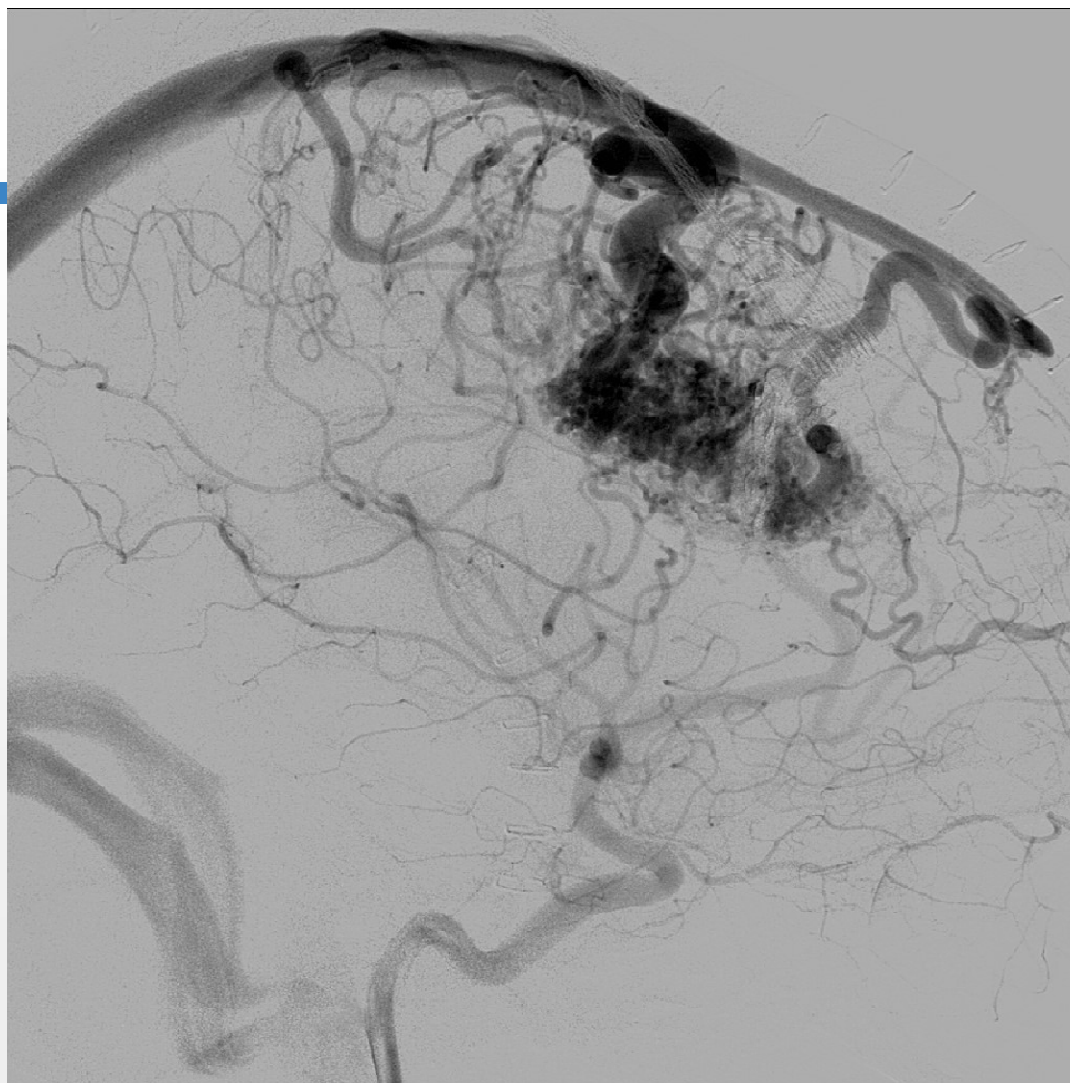


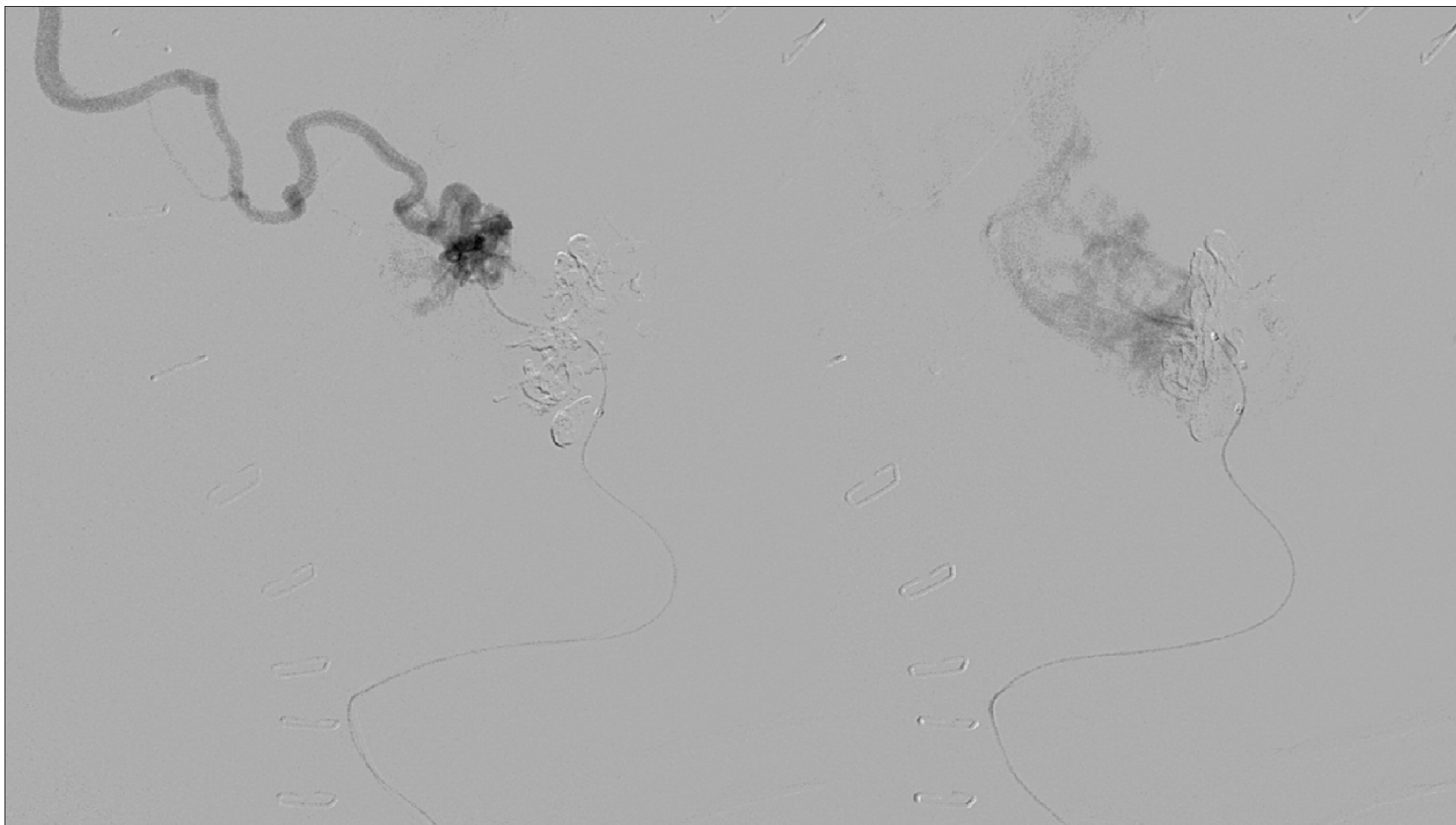
Clinical History

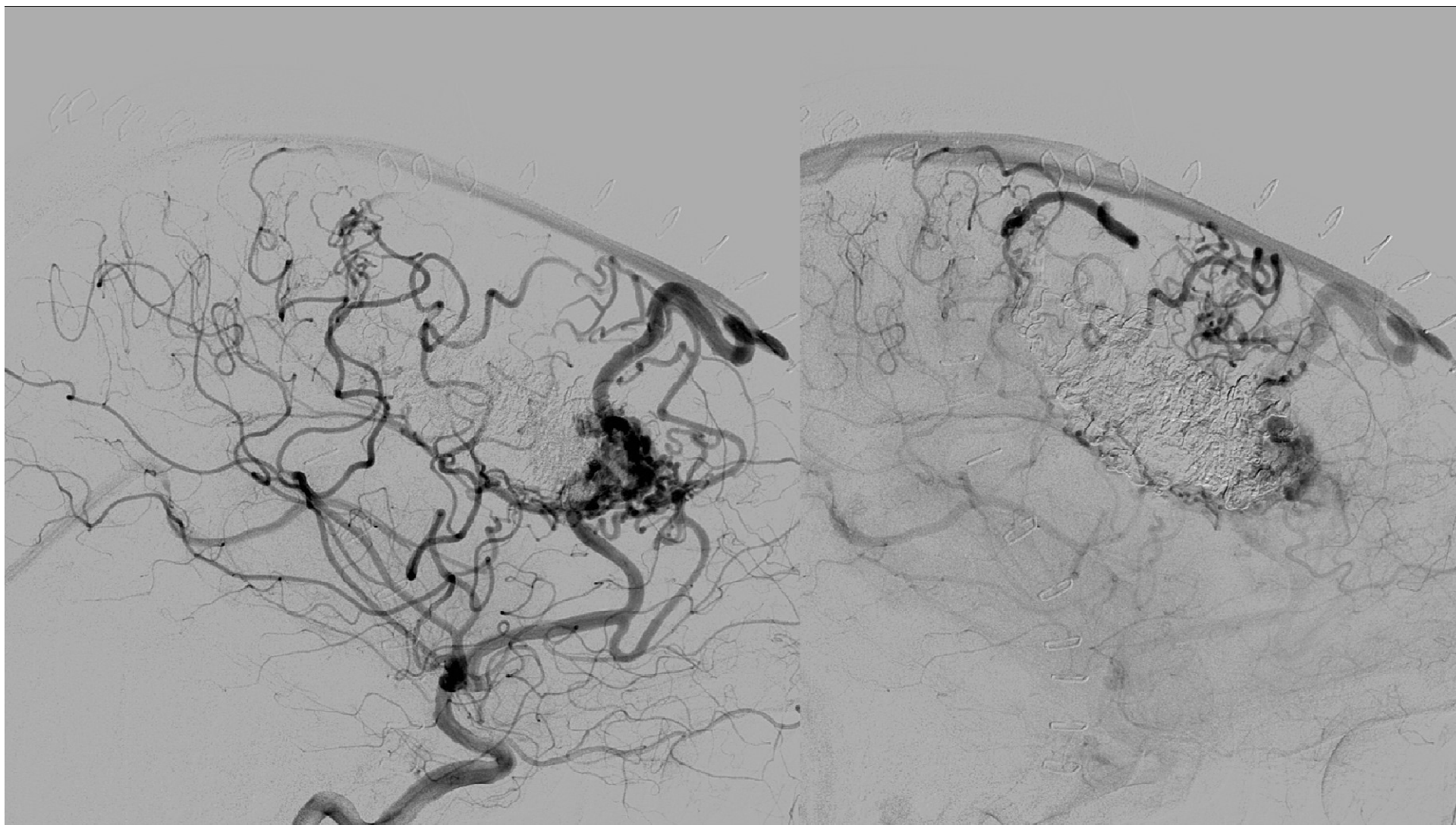
1. Acute bleeding with big intraparenchymal hematoma
2. Treated acutely with embolization of pseudoaneurysm
3. Decompressive craniectomy
4. Left for further embolization during admission

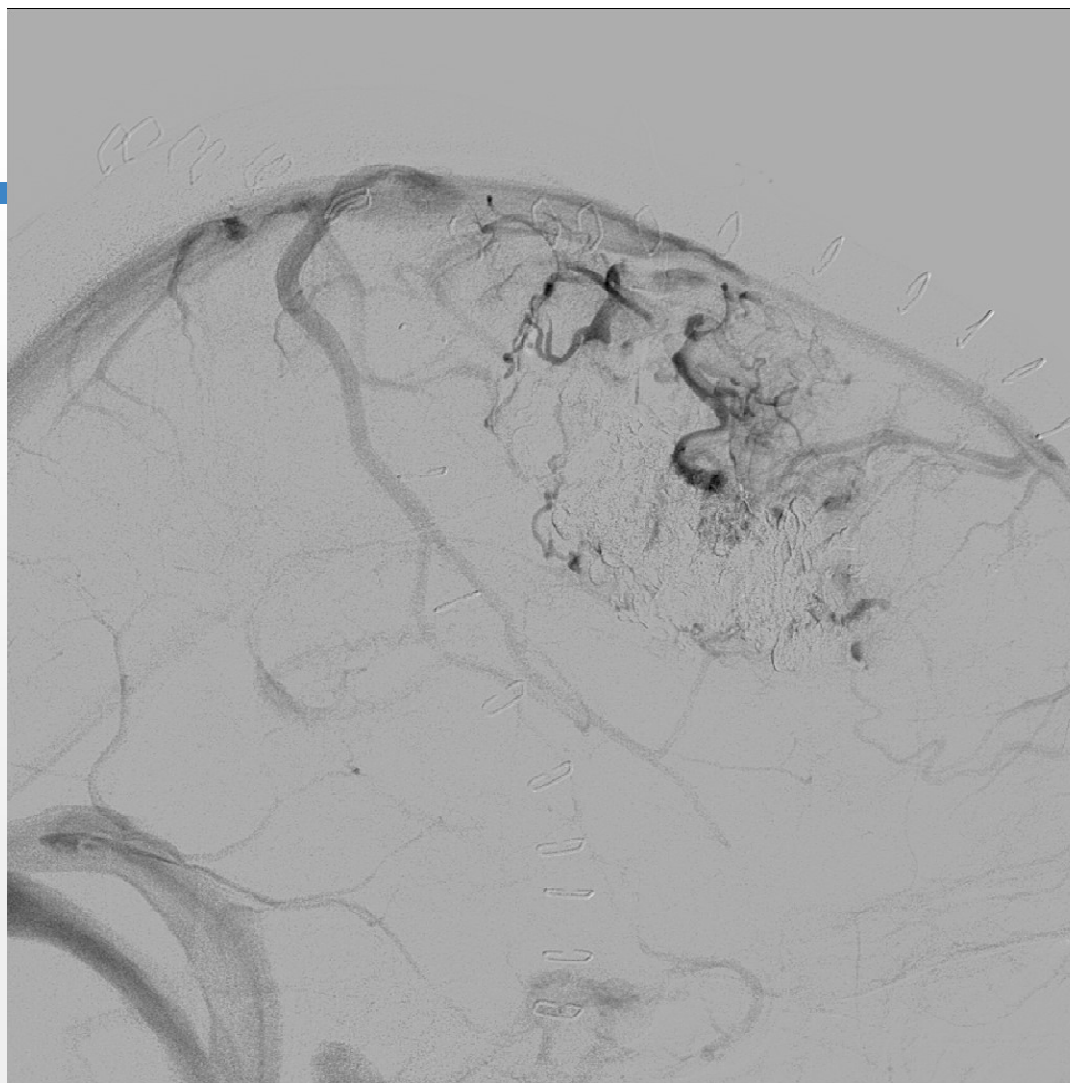




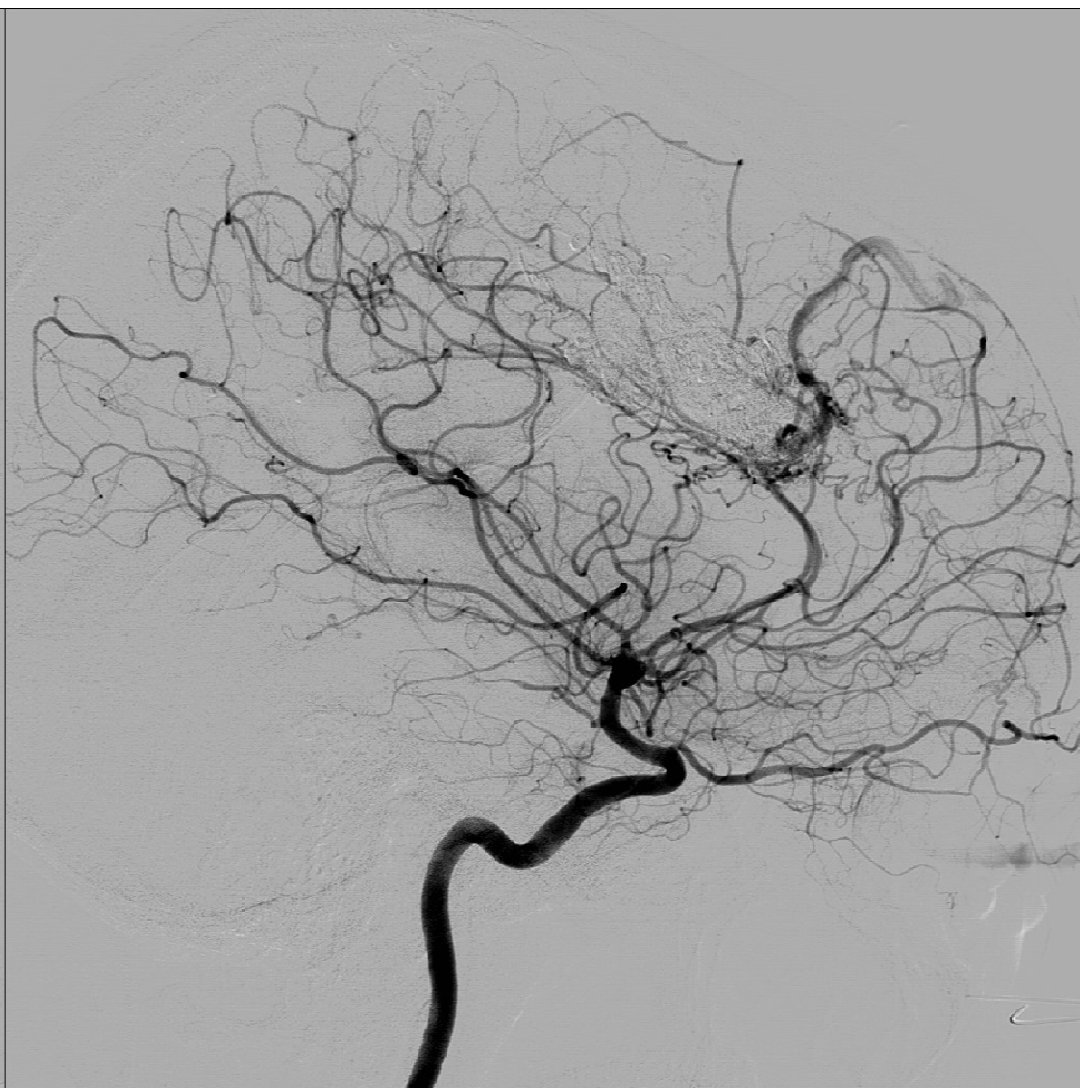
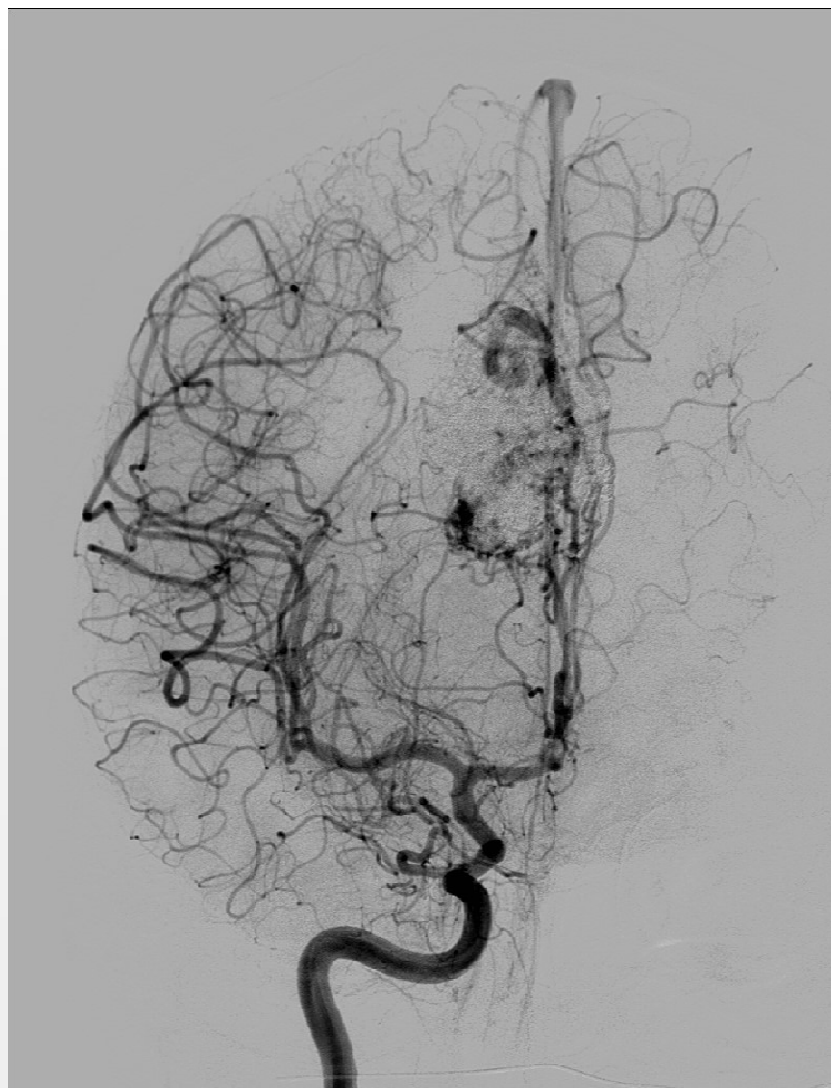


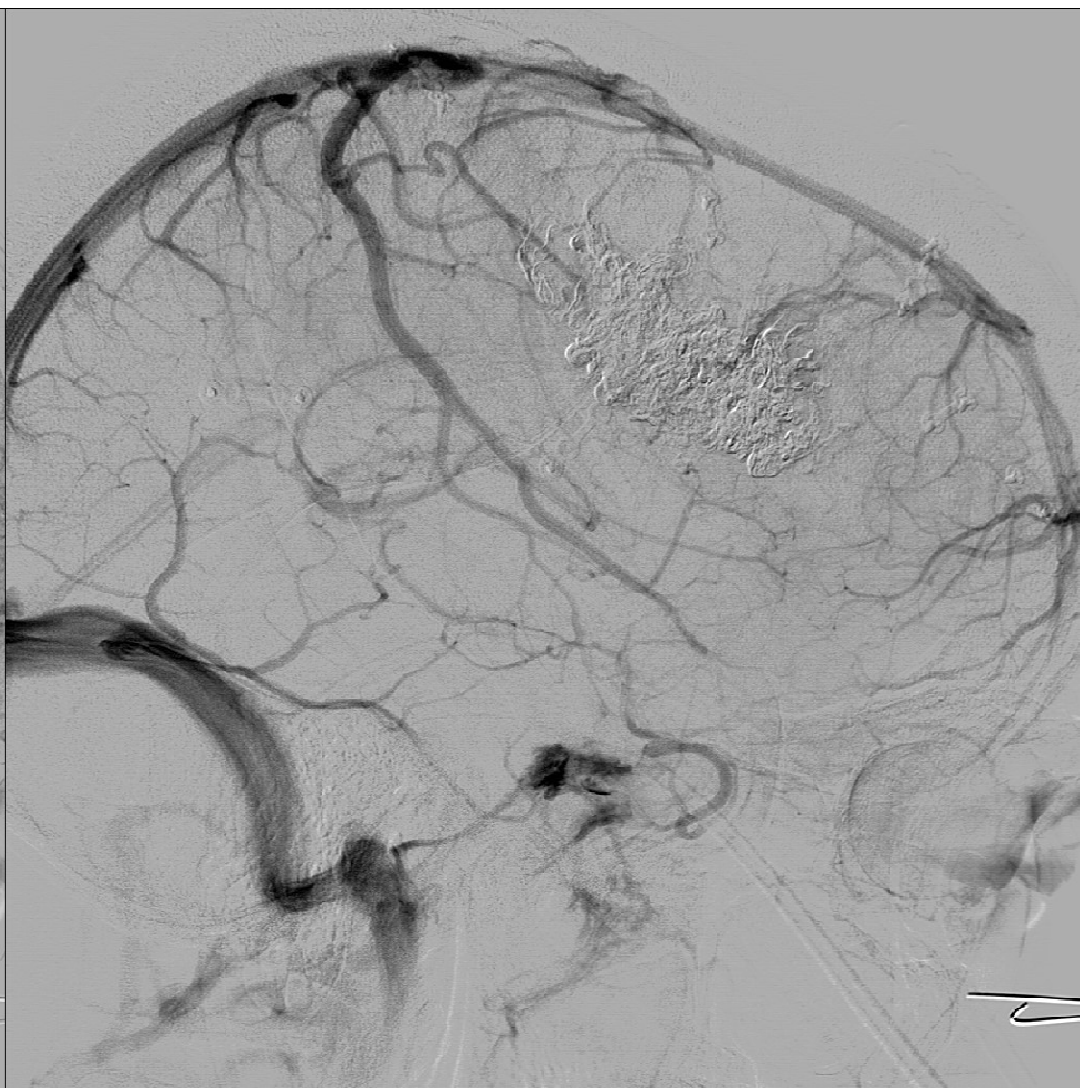
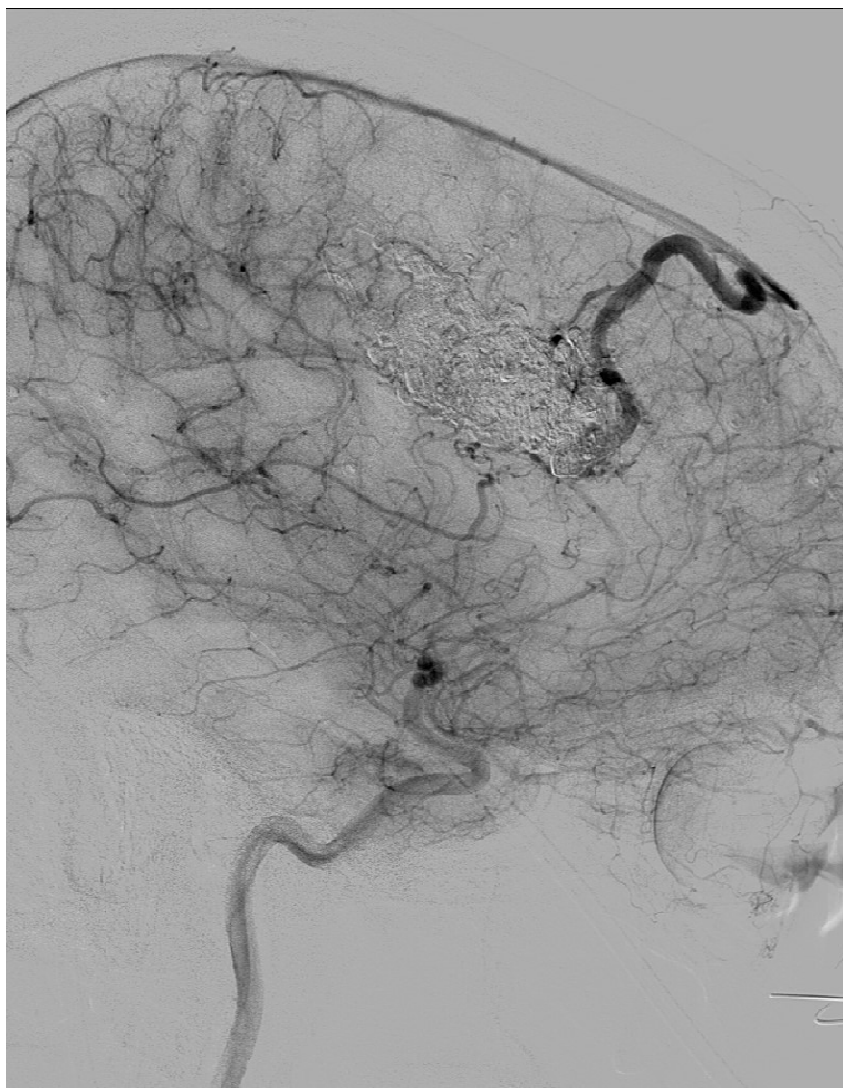




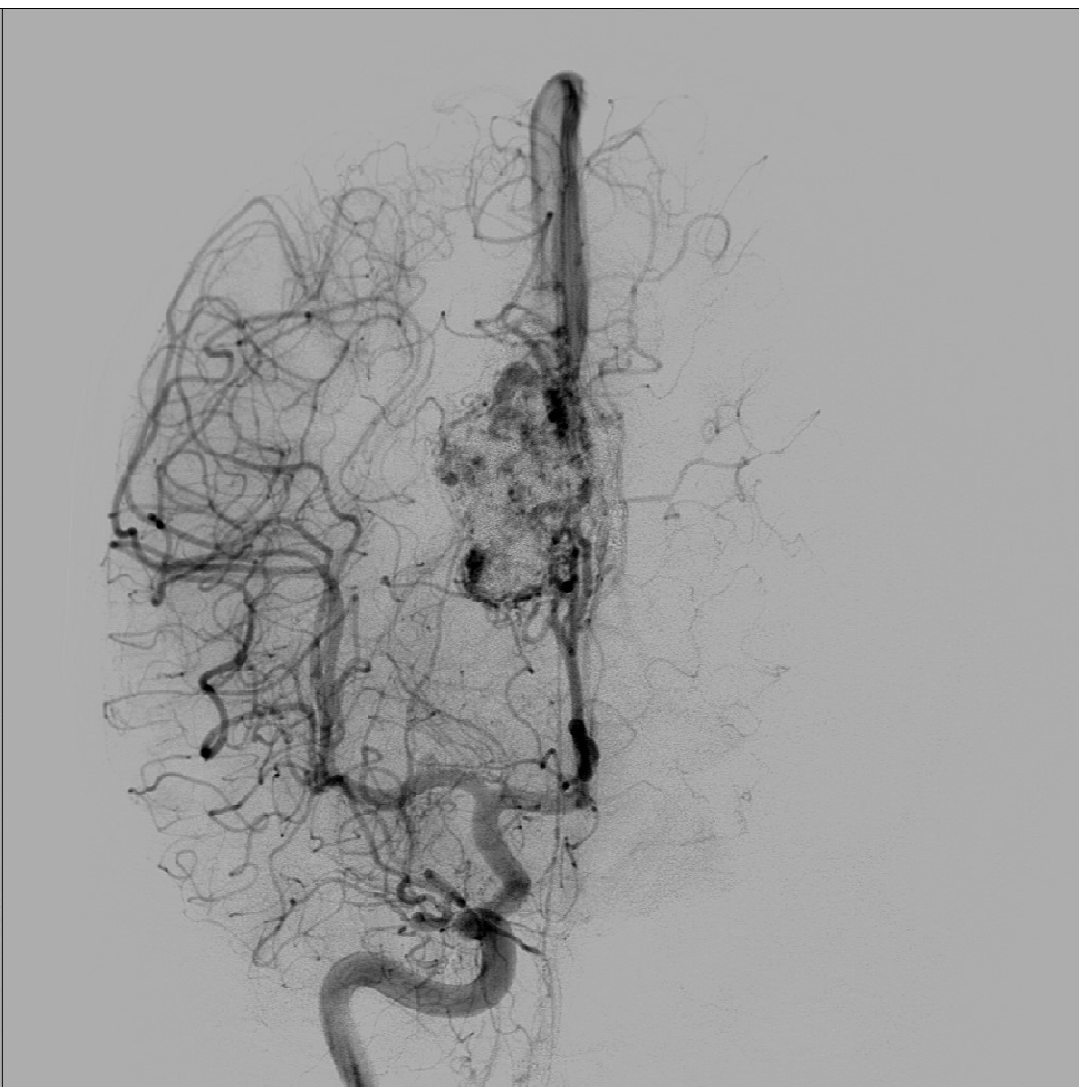
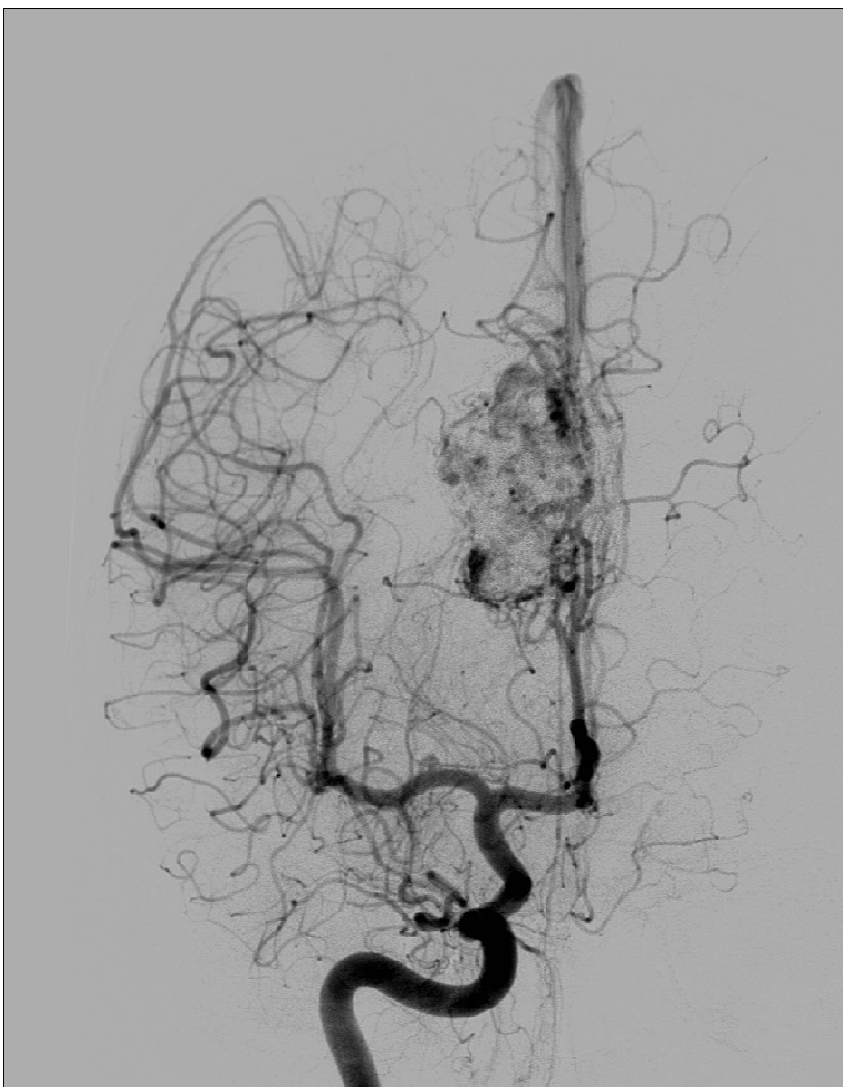


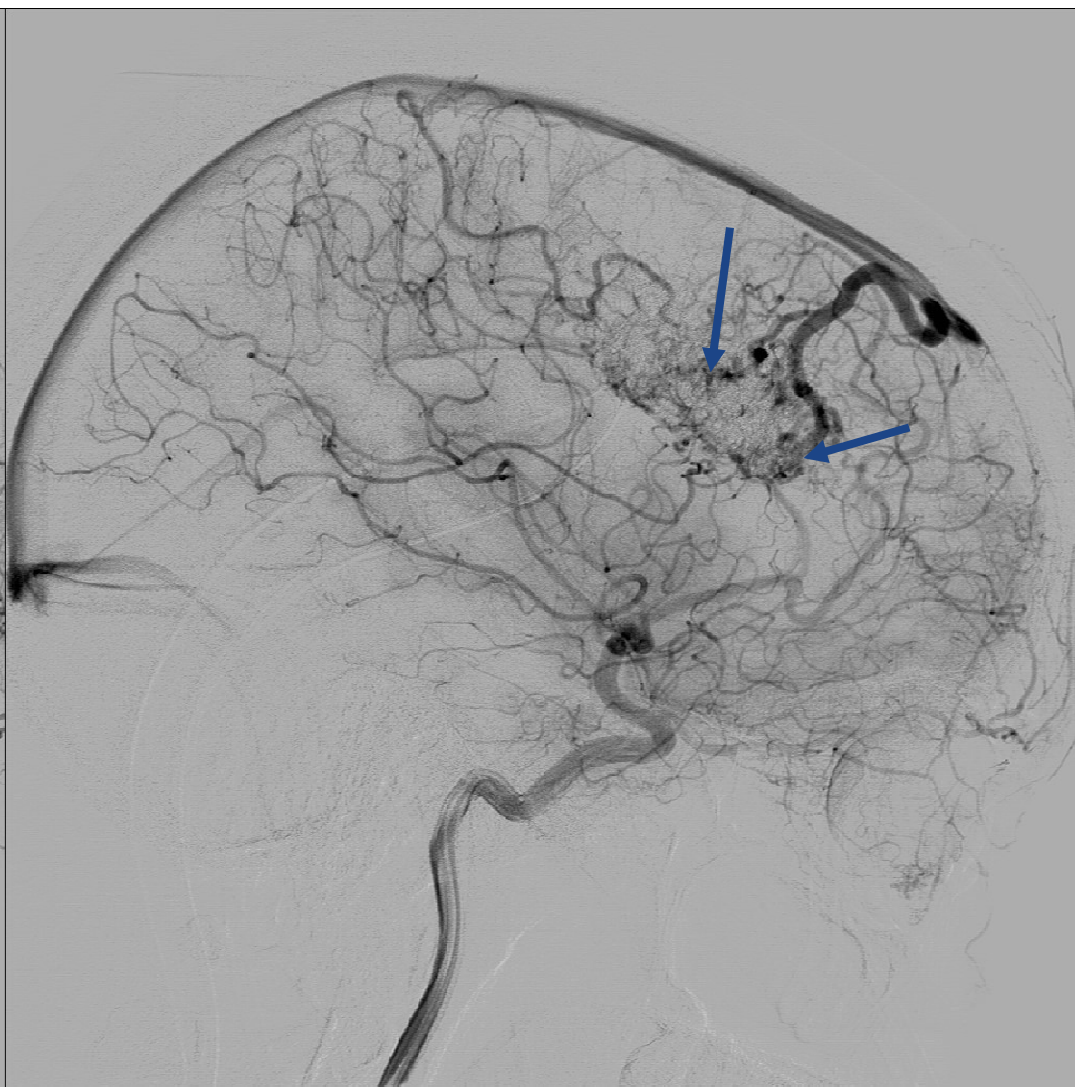
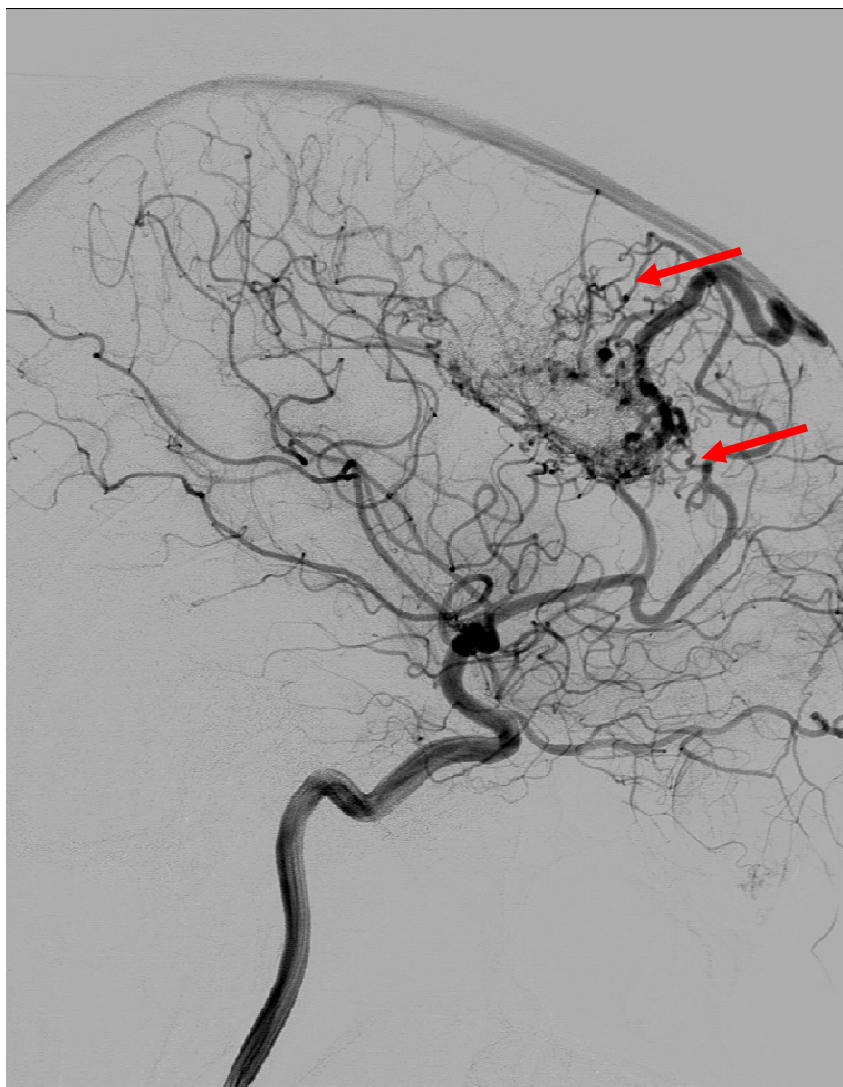
One month after





3 months fu





Venous embolization
